Parasitology Exam (Blood Parasite images)
Answers will be found at the end.

****Reminder: Slides and examination questions are copyrighted and cannot be copied for publication.*

1. The following stained blood images are (oil immersion power, 1000x):

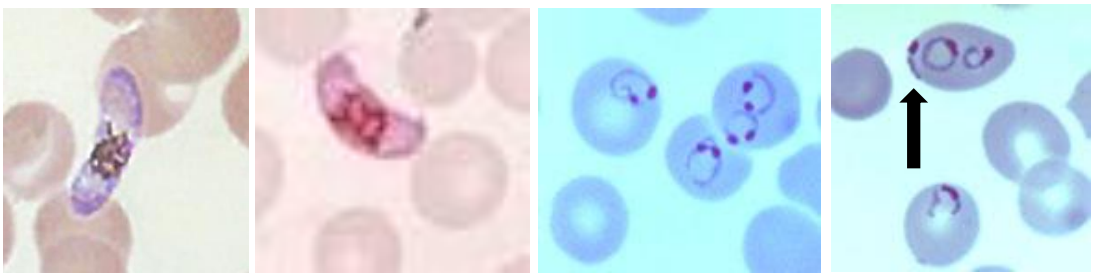

A. *Plasmodium falciparum*
B. *Plasmodium knowlesi*
C. *Plasmodium vivax*
D. *Plasmodium ovale*

2. The following stained blood images are (oil immersion power, 1000x):

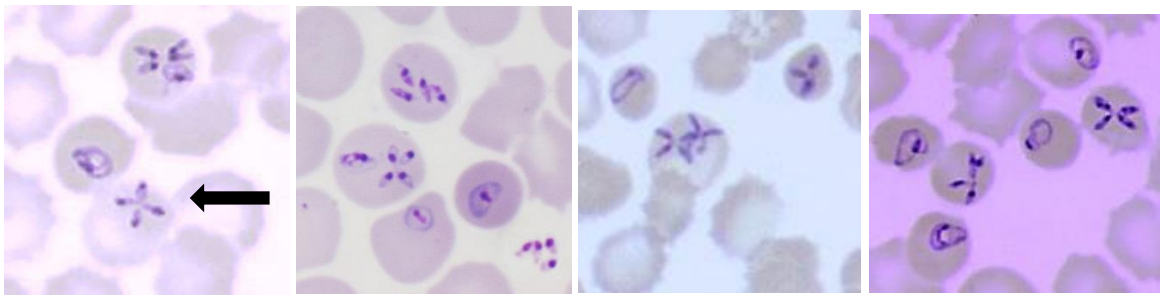

A. *Plasmodium knowlesi*
B. *Babesia* spp.
C. *Babesia microti*
D. *Plasmodium malariae*

3. **The following stained blood images are (oil immersion power, 1000x):**

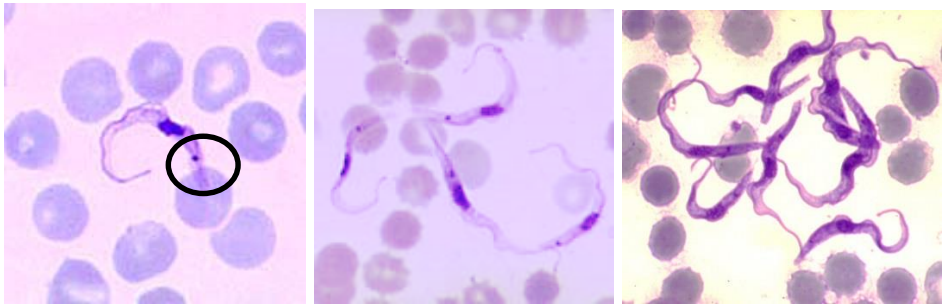

A. *Trypanosoma cruzi*
B. *Trypanosoma rangeli*
C. *Trypanosoma rhodesiense*
D. *Trypanosoma brucei rhodesiense* or *T. b. gambiense*

4. **The following stained blood images are (oil immersion power, 1000x):**

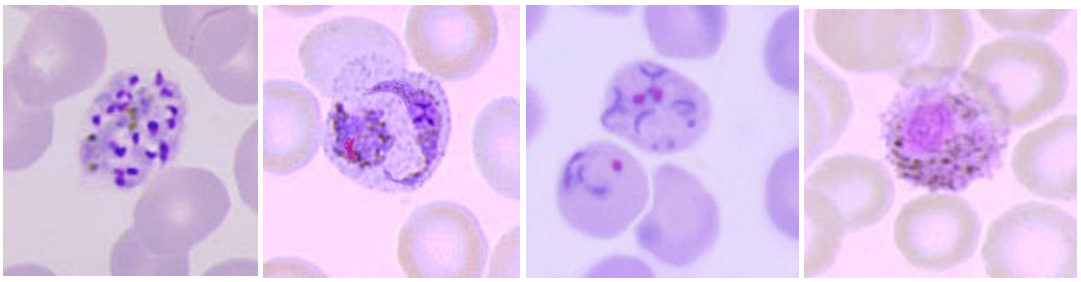

A. *Plasmodium knowlesi*
B. *Plasmodium falciparum*
C. *Plasmodium vivax*
D. *Plasmodium ovale*

5. **The following stained blood images are (oil immersion power, 1000x):**

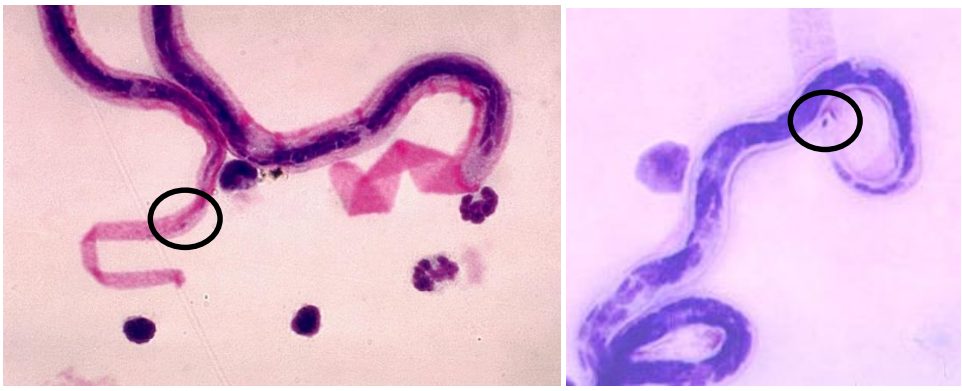

A. *Loa loa*
B. *Brugia malayi*
C. *Onchocerca volvulus*
D. *Wuchereria bancrofti*

6. The following stained blood images are (oil immersion power, 1000x):

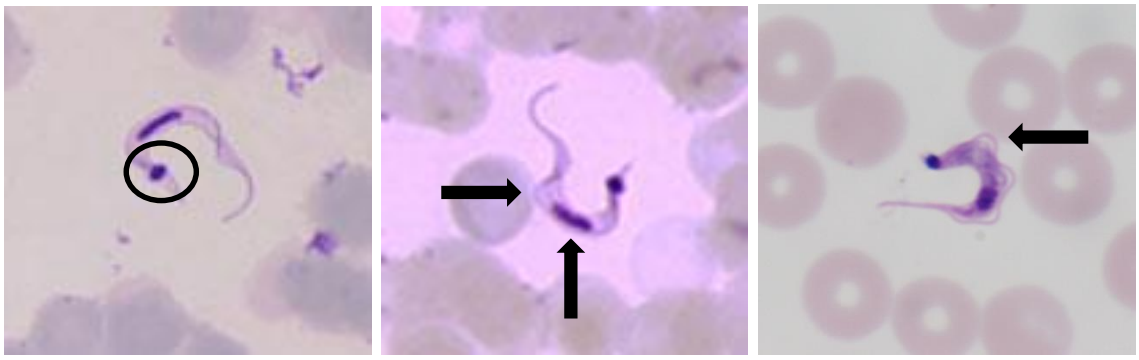

A. *Trypanosoma gambiense*
B. *Trypanosoma cruzi*
C. *Trypanosoma rhodesiense*
D. None of the above

7. The following stained blood images are (oil immersion power, 1000x):

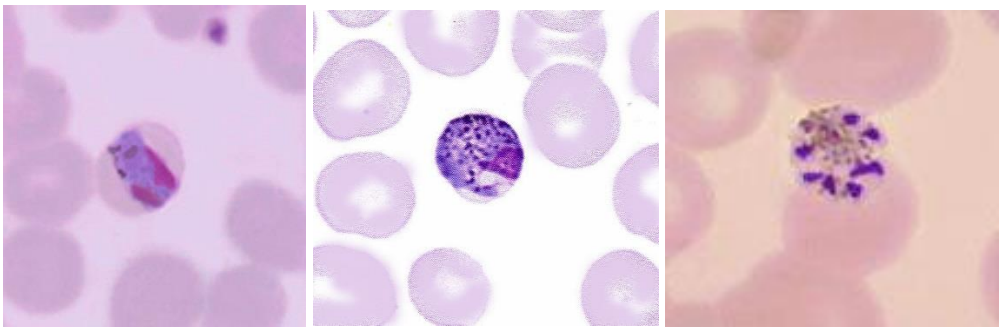

A. *Plasmodium malariae*
B. *Plasmodium vivax*
C. *Plasmodium ovale*
D. *Plasmodium knowlesi*

8. The following stained blood images are (oil immersion power, 1000x):

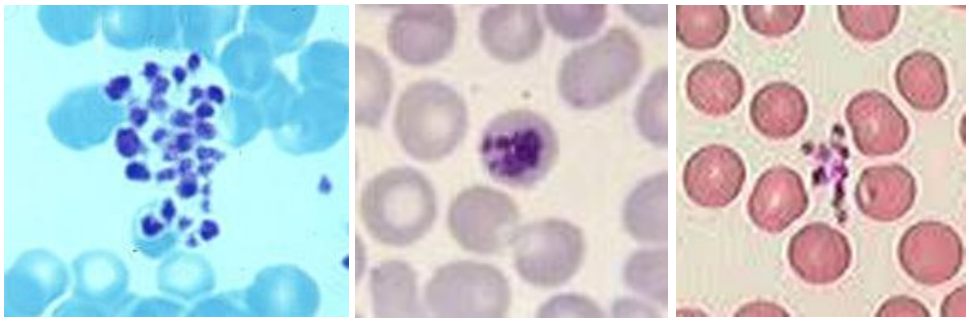

A. *Toxoplasma gondii*
B. *Plasmodium falciparum*
C. *Leishmania* spp.
D. Artifacts and platelets

9. The following stained blood images are (oil immersion power, 1000x):

A. *Wuchereria bancrofti*
B. Brugia malayi
C *Onchocerca volvulus*
D. *Loa loa*

10. The following stained blood images are (oil immersion power, 1000x):

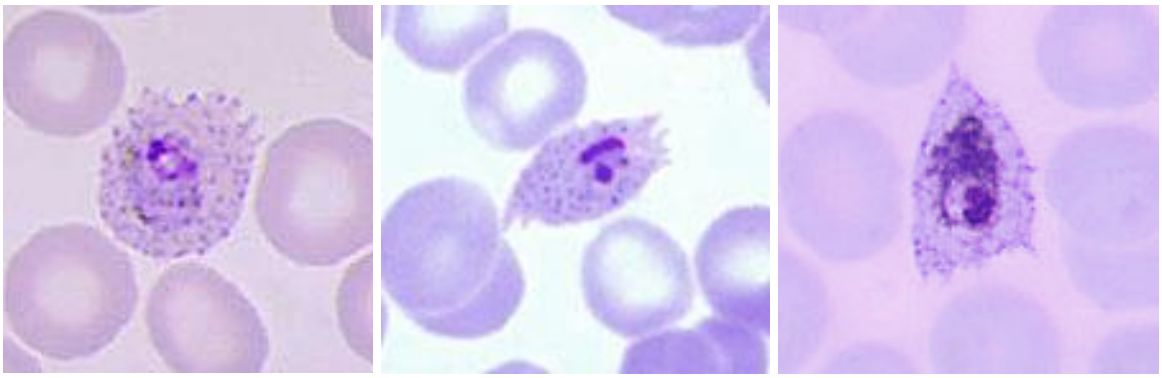

A. *Plasmodium knowlesi*
B. *Plasmodium vivax*

C. *Plasmodium ovale*
D. *Plasmodium malariae*

11. The following stained bone marrow images are (oil immersion power, 1000x):

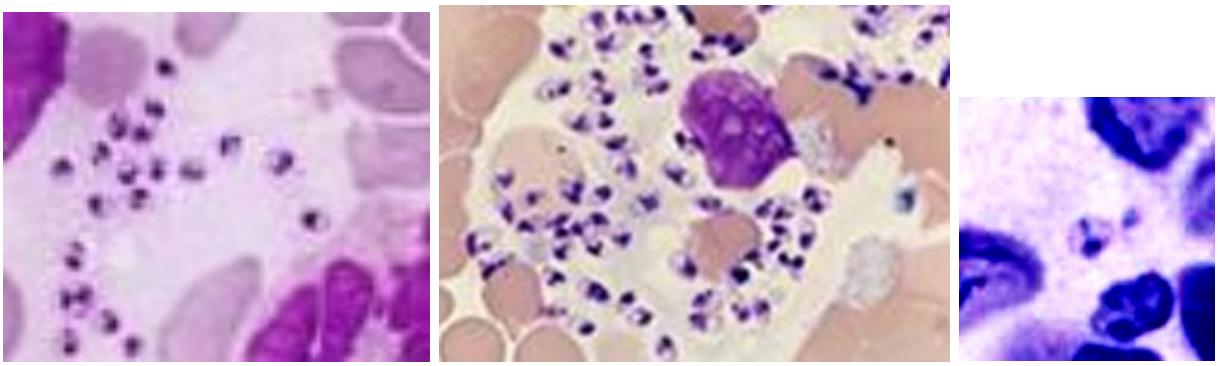

A. *Plasmodium falciparum*
B. *Leishmania donovani*
C. *Toxoplasma gondii*
D. *Leishmania* spp.

12. The following stained blood images are (oil immersion power, 1000x):

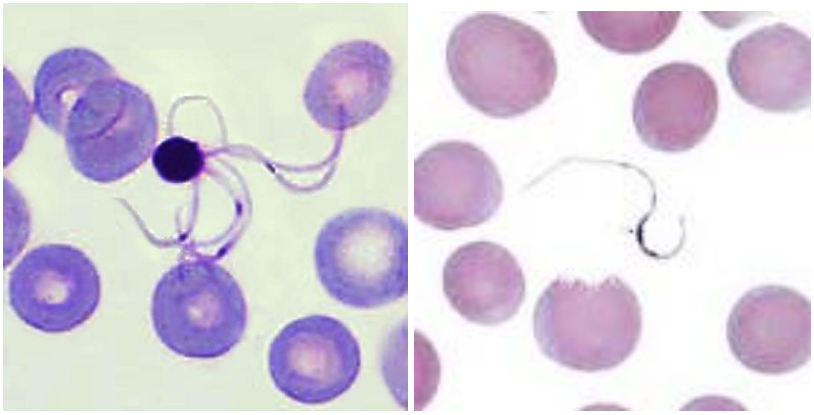

A. *Borrelia*
B. Abnormal platelets
C. Exflagellating male *Plasmodium* gametocytes
D. *Trypanosoma gambiense*

13. The following stained blood images are (oil immersion power, 1000x): How should these findings be reported?

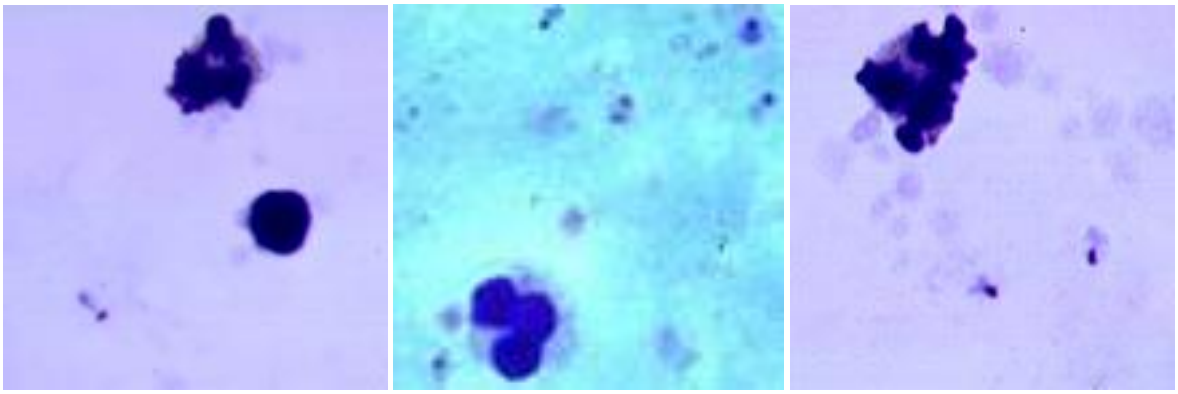

A. *Toxoplasma gondii*
B. *Leishmania* spp. amastigotes
C. *Plasmodium falciparum* rings present, no gametocytes seen
D. *Plasmodium* spp. rings present, no gametocytes seen

14. The following stained blood images are (oil immersion power, 1000x): These are photographed from thick blood films.

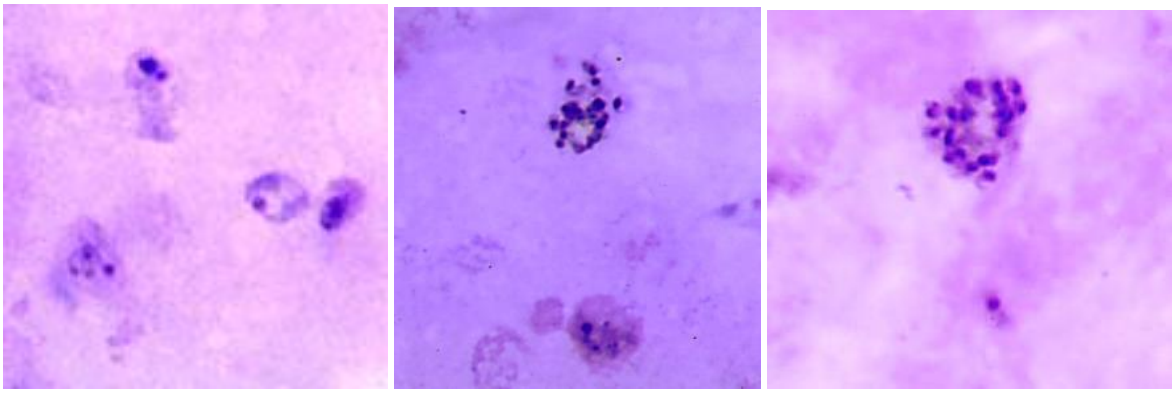

A. *Plasmodium vivax*
B. *Plasmodium ovale*
C. *Plasmodium malariae*
D. *Plasmodium falciparum*

15. The following stained blood images are (oil immersion power, 1000x):

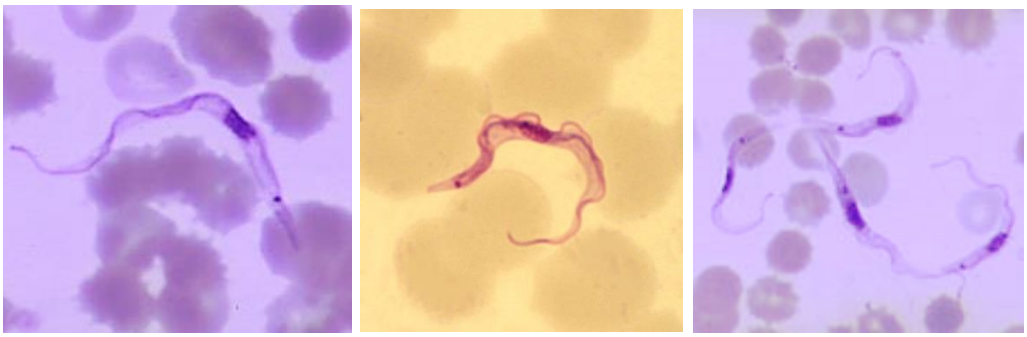

A. *Trypanosoma gambiense*
B. *Trypanosoma rhodesiense or T. gambiense*
C. *Trypanosoma cruzi*
D. *Trypanosoma rhodesiense*

16. The following stained blood images are (oil immersion power, 1000x):

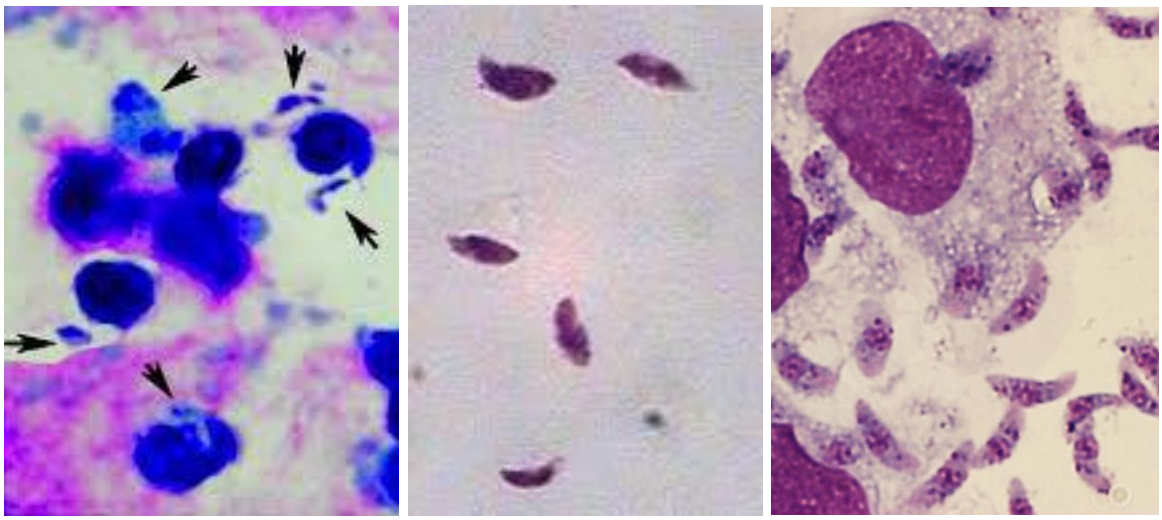

A. Artifacts
B. *Leishmania* spp.
C. *Plasmodium falciparum*
D. *Toxoplasma gondii*

17. The following stained blood images are (oil immersion power, 1000x):

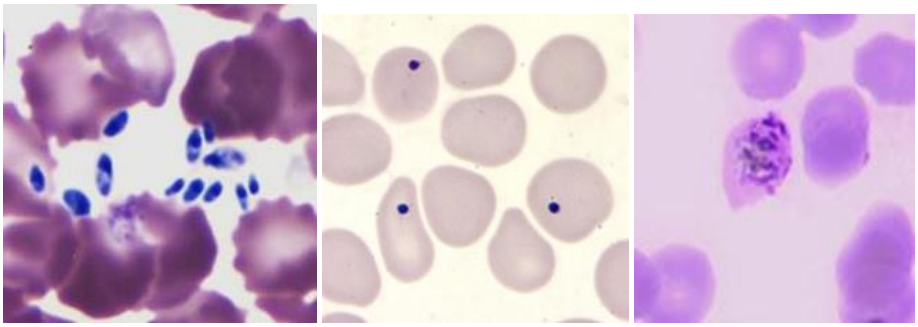

A. Artifacts
B. *Plasmodium* spp.
C. *Leishmania* spp.
D. Microsporidian spores

18. The following stained blood images are (oil immersion power, 1000x):

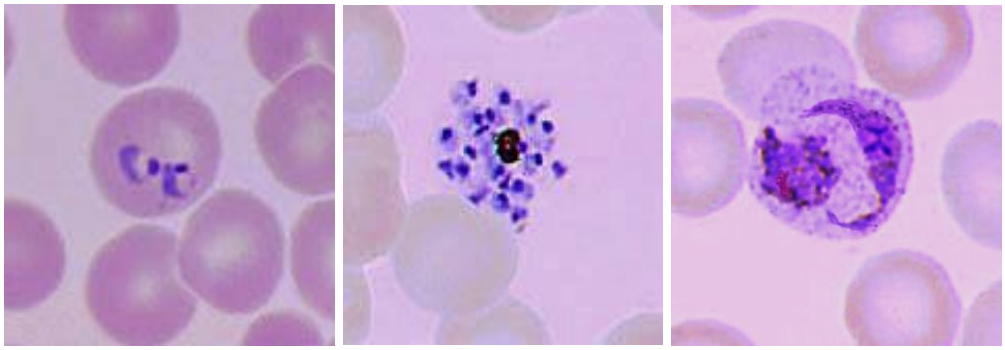

A. *Plasmodium ovale*
B. *Plasmodium falciparum*
C. *Plasmodium knowlesi*
D. *Plasmodium vivax*

19. The following stained blood images are (oil immersion power, 1000x):

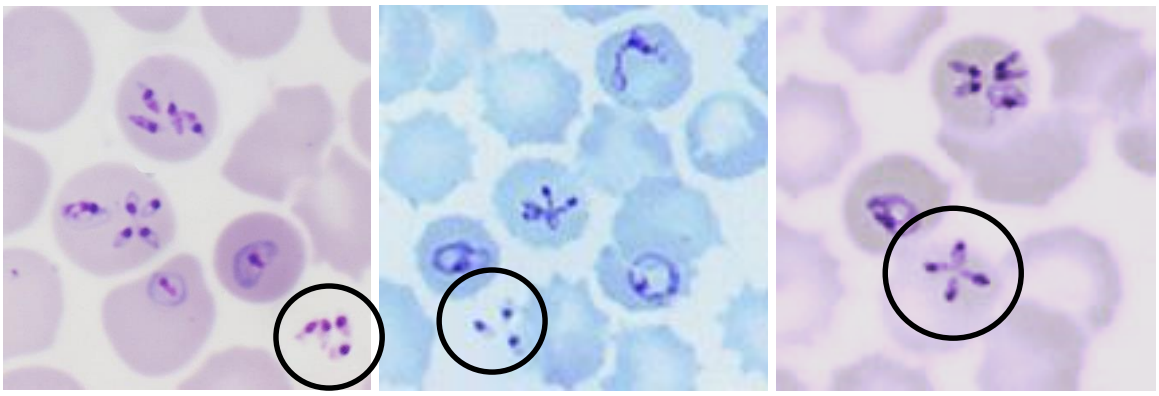

A. *Plasmodium falciparum*
B. *Babesia* spp.
C. *Leishmania donovani*
D. *Plasmodium knowlesi*

20. The following stained blood images are (oil immersion power, 1000x):

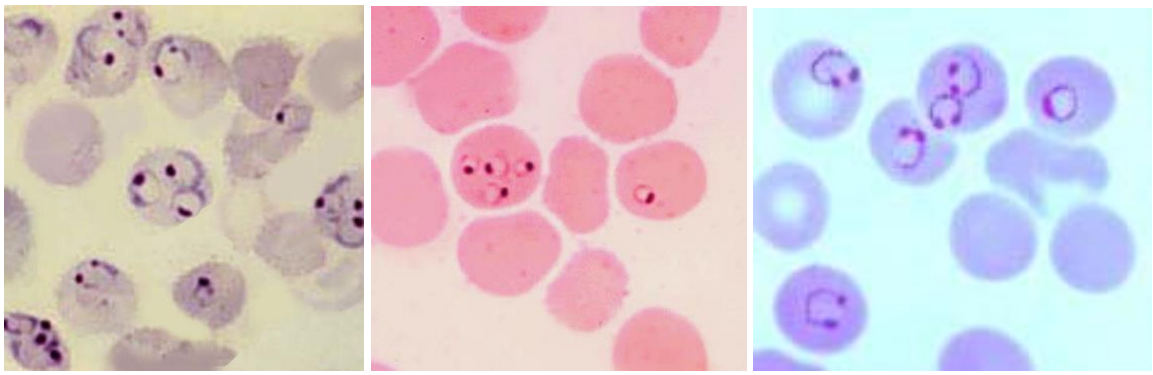

A. *Plasmodium malariae*
B. *Babesia* spp.
C. *Plasmodium vivax*
D. *Plasmodium falciparum*

21. The following stained blood images are (oil immersion power, 1000x):

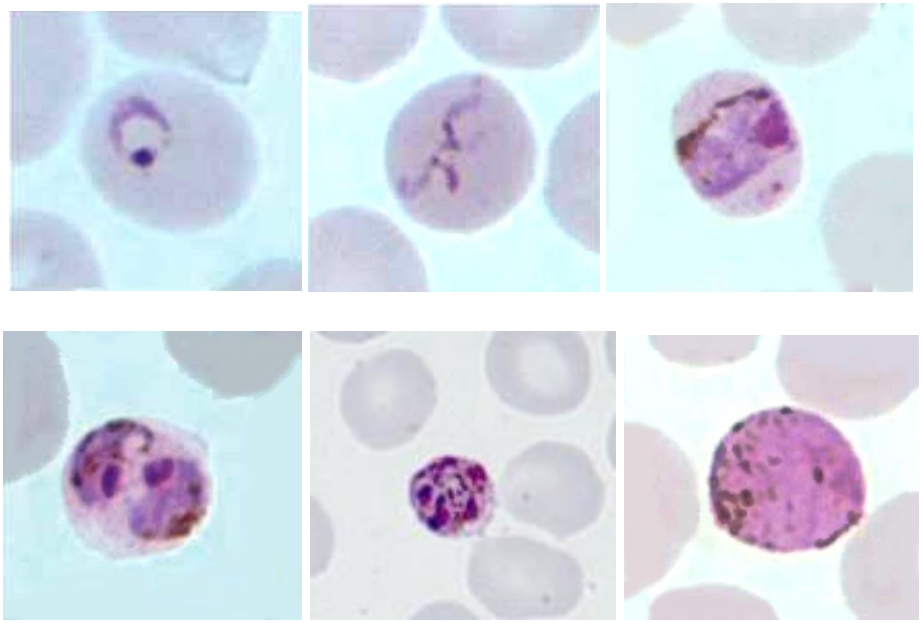

A. *Plasmodium falciparum* and *Plasmodium malariae*

B. *Plasmodium malariae*
C. *Plasmodium vivax* and *Plasmodium malariae*
D. *Plasmodium knowlesi*

22. The following stained blood images are (oil immersion power, 1000x):

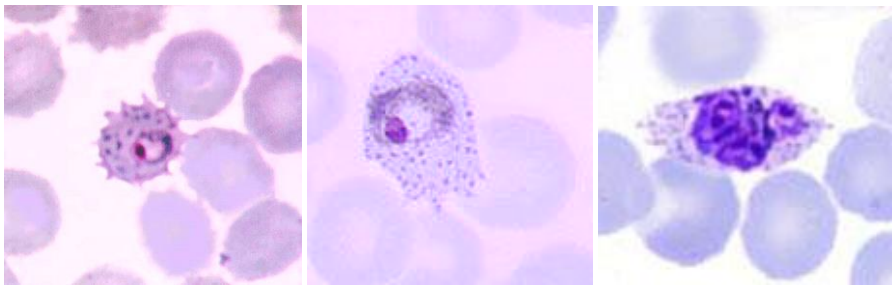

A. *Plasmodium ovale*
B. *Plasmodium malariae*
C. *Plasmodium vivax*
D. *Plasmodium knowlesi*

23. The following stained blood images are (oil immersion power, 1000x):

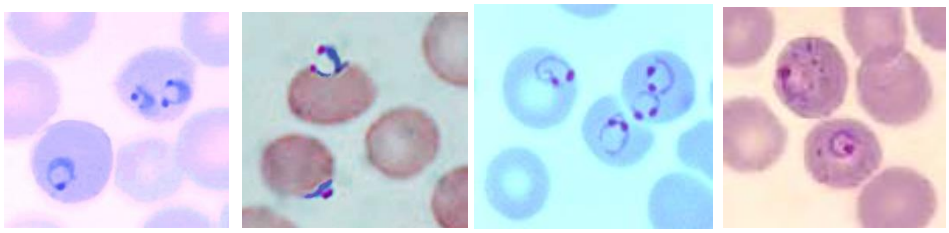

A. *Babesia* spp.
B. *Plasmodium malariae*.
C. *Plasmodium falciparum*
D. *Plasmodium vivax*

24. The following stained blood images are (oil immersion power, 1000x):

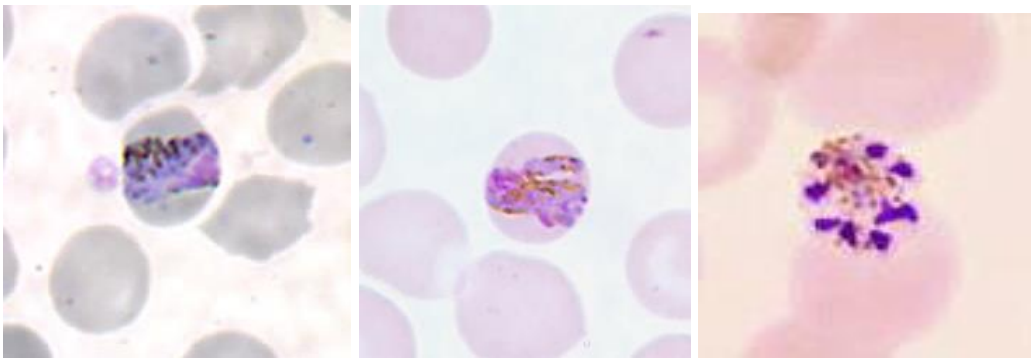

A. *Plasmodium vivax*
B. *Plasmodium knowlesi*
C. *Plasmodium malariae*
D. *Plasmodium falciparum*

25. The following stained blood images are (oil immersion power, 1000x):

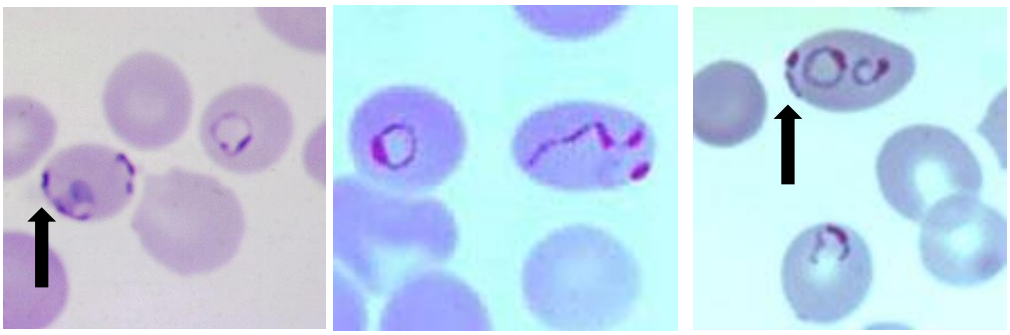

A. *Plasmodium vivax*
B. *Plasmodium falciparum*
C. *Babesia microti*
D. *Babesia* spp.

ANSWERS:

ANSWER. 1. A. These images represent *Plasmodium falciparum*. Note the typical crescent-shaped gametocytes, the double rings/cell and the appliqué or accolé form (arrow), and the "headphone" ring shapes (middle right image). All of these morphological details are very typical for *P. falciparum*. NOTE: ALL REQUESTS FOR BLOOD PARASITE IDENTIFICATION ARE STAT (ordering, collection, processing, testing, examination, and reporting)!!!! For therapy reasons, this report should read: "*Plasmodium falciparum*, rings and gametocytes seen"

ANSWER. 2. B. These organisms are *Babesia* spp.; morphology of the various human species are identical. Thus, without additional patient information, it would be difficult to identify to the species level. Although in the far left image one can see the typical "Maltese Cross" formation (arrow), this configuration of the rings does not always appear in a patient blood film. Note that the rings tend to be very pleomorphic and small, with many ring forms per cell. Most patients who are not living in an endemic area for malaria (immunologically naïve – no antibody – travelers) will present with a much lower parasitemia than seen in these images; thus the parasitemia may help differentiate between *Babesia* and *Plasmodium* infections.

ANSWER 3. D. The correct response is *Trypanosoma brucei rhodesiense* or *T. b. gambiense* (African trypanosomiasis). The East and West African forms of the infection are caused by *Trypanosoma brucei*, but the subspecies determination can't be made on the basis of trypomastigote/trypanosome morphology. Since the East African form with *T. b. rhodesiense* is a much more serious illness, additional clinical and patient history information may help differentiate the two. These organisms can be differentiated from American trypanosomiasis caused by *Trypanosoma cruzi* as follows: The African trypomastigotes have a very small kinetoplast (circle), while *T. cruzi* has a very large kinetoplast. Also, the African trypomastigotes multiply within the blood (far right image), while *T. cruzi* do not.

ANSWER. 4. C. These organisms are *Plasmodium vivax.* From left to right, the stages are: mature schizont, developing trophozoite (ameboid), developing trophozoites (ameboid) (no Schüffner's dots – may be due to pH of buffer and/or age of the blood prior to blood film preparation), and mature gametocyte. One of the key characteristics is the fact that the infected RBCs are enlarged, unlike many of the other species. For therapy reasons, the report should be: "*Plasmodium vivax* developing rings and gametocytes seen"

ANSWER. 5. B. These organisms are *Brugia malayi* microfilariae. Note that with Giemsa stain, the sheath will stain pink. One of the key characteristics is the presence of the terminal nucleus (circles). In the left image, the sheath can be seen beyond the head and the tail.

ANSWER. 6. B. The correct identification is *Trypanosoma cruzi*, the cause of American Trypanosomiasis (formerly known as South American Trypanosomiasis). Note the large kinetoplast (oval) when compared with that seen in the African trypomastigotes (see challenge 3). Also the trypomastigotes of *T. cruzi* often tend to be seen in a "C" configuration. Note the large nucleus and undulating membrane (arrows).

ANSWER. 7. A. The correct identification is *Plasmodium malariae*, the cause of quartan malaria. The stages from left to right are: band form developing trophozoite, mature gametocyte, mature schizont ("daisy arrangement" of merozoites). Note that the infected RBCs are small to normal size, not enlarged like those seen in *P. vivax* or *P. ovale*. For therapy reasons, the report should be: "*Plasmodium malariae* developing rings and gametocytes seen". It is also important to remember that *Plasmodium knowlesi* can mimic a *P. malariae* infection or a mixed infection with *P. falciparum* (rings) and *P. malariae.*

ANSWER. 8. D. These images are of artifacts and platelets; no parasites are present. Parasites tend to have consistent shapes and sizes, while artifact material is somewhat random. Some platelets are seen in the right image.

ANSWER. 9. A. These images are consistent with *Wuchereria bancrofti* microfilariae. The stain is a hematoxylin, since the sheath of this organism does

not stain well using Giemsa stain. In the left image, note the tail nuclei stop and the tail continues to the end; this morphology showing an empty tail space and sheath is typical for *W. bancrofti* (oval). In the right image, note the sheath and head space. Also note the nuclei are quite precise and do not flow together; they are individual "dots" – not typical for some of the other microfilariae.

ANSWER 10. C. These structures are developing rings/trophozoites of *Plasmodium ovale*. Note the enlarged RBCs, the fimbriated RBC cell edges, and the symmetric (non-ameboid) trophozoite, unlike the asymmetric (ameboid) developing trophozoites of *Plasmodium vivax*. In the images below, note the *P. ovale* developing ring is very symmetric (non-ameboid), while the developing ring of *P. vivax* is very asymmetrical (ameboid). For therapy reasons, the report should be: "*Plasmodium ovale* developing rings; no gametocytes seen"

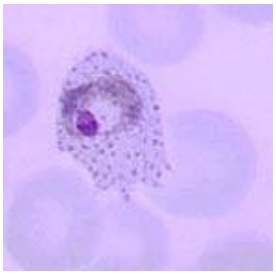

Plasmodium ovale

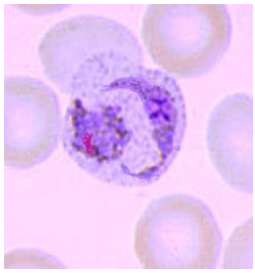

Plasmodium vivax

ANSWER. 11. B. The correct response is *Leishmania donovani*. In the images one can see the typical amastigote forms with the dot nucleus and the linear kinetoplast (see far right image). Because this is a bone marrow specimen, the organism is *Leishmania donovani*, the cause of visceral leishmaniasis.

ANSWER 12 C. These structures are male gametocytes of *Plasmodium* sp. that are undergoing exflagellation. While this stage within the malaria life cycle normally occurs within the mosquito, if blood is collected using EDTA (lavender top) and stands with the lid removed and the blood cooled to room temperature, any male gametocytes may begin the cycle found in the mosquito. These "artifacts" can easily be misidentified as spirochetes, possibly *Borrelia*. This error can easily occur if a single strand is seen like that in the right image.

ANSWER. 13. D. These images represent *Plasmodium* spp. ring forms. The parasitemia varies among the three images. Although the middle image (relatively high parasitemia) strongly suggests *P. falciparum*, there is no way to rule out *P. knowlesi*. So, the correct report: *Plasmodium* spp. rings present, no gametocytes seen. "Unable to rule out either *P. falciparum* or *P. knowlesi*"

ANSWER. 14. A. Based on the number of merozoites seen in the mature schizonts, the correct identification should be *Plasmodium vivax.* Developing

rings can be seen in the left image. If no gametocytes are seen throughout the smear, then the report should be: "*Plasmodium vivax*; no gametocytes seen"

ANSWER 15. B. Based on the overall morphology (very small kinetoplast) and appearance of multiplication (right image), the correct identification would be *Trypanosoma rhodesiense* or *T. gambiense* (African trypanosomiasis). The report could also be: *Trypanosoma brucei rhodesiense* or *T. b. gambiense*. Note the dividing trypomastigotes in the right image. *Trypanosoma cruzi* will not divide in the peripheral blood and the *T. cruzi* kinetoplast is quite large (see below).

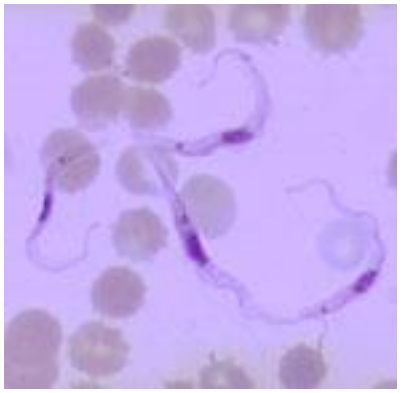

Trypanosoma rhodesiense/gambiense

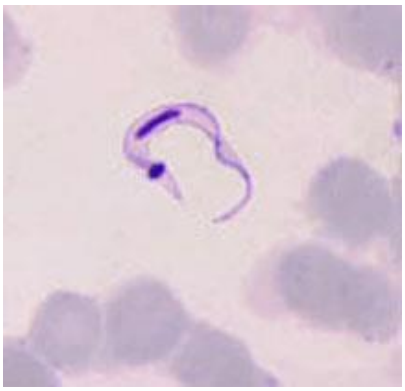

Trypanosoma cruzi

ANSWER. 16. D. These structures are *Toxoplasma gondii* tachyzoites (actively growing forms – not the resting bradyzoite forms). They appear as somewhat crescent-shaped organisms (not as large as crescent-shaped gametocytes of *Plasmodium falciparum*). Note they can be seen as intracellular or extracellular organisms.

ANSWER. 17. A. These structures are artifacts that could mimic *Plasmodium* spp, *Babesia* spp. or microsporidian spores. However, there are no morphological characteristics that would confirm the presence of actual parasites. These artifacts would not be reported.

ANSWER. 18. D. These structures are *Plasmodium vivax*. Note the double rings in the left image. Often people think double rings are limited to *Plasmodium falciparum*; however, this is not the case and they can often be seen in smears of *P. vivax*. Note the number of merozoites in the mature schizont (middle image) and the ameboid developing ring form (right image) – all images that are consistent with *P. vivax*. The report should be: *Plasmodium vivax*; no gametocytes seen (the presence/absence of gametocytes will influence therapy).

ANSWER. 19. B. These structures are *Babesia* spp; identification to the species level is not possible based on morphology. Note the multiple rings within the RBCs. Also note the ring forms outside of the RBCs (left and middle images -

circles). Finding extracellular merozoites is extremely rare in an infection with *Plasmodium* spp.; when the merozoites are released from the mature schizont, each merozoite immediately attaches to and penetrates another RBC. In the right image one can see the Maltese Cross configuration (circle). Although this formation of the four rings is very helpful in identifying *Babesia* organisms, the cross formation is not always seen in patient smears.

ANSWER. 20. D. These images represent *Plasmodium falciparum*. Note the multiple rings per RBC; the left image represents a very heavy parasitemia. In the right image, note the typical headphone appearance of the ring forms (two chromatin dots per ring form). This configuration of the ring forms is much more typical for *P. falciparum* than the other species; also note the heavy parasitemia in this right image. The report should be: "*Plasmodium falciparum* ring forms; no gametocytes seen". It is important to note that a heavy parasitemia of ring forms could also represent *Plasmodium knowlesi*; however, the overall morphology of these images makes it more likely to be *P. falciparum*.

ANSWER. 21. A/D. These images represent *Plasmodium knowlesi*; however, often these images will be identified as a mix of *Plasmodium falciparum* (ring forms) and *Plasmodium malariae* (developing forms: band forms, typical schizonts and gametocytes). Although *P. knowlesi* is somewhat limited in terms of geographic distribution (Malaysia), this species has been diagnosed in many other parts of the world in travelers. IF A MIX (*P. falciparum/P. malariae*) IS REPORTED, A REPORT COMMENT SHOULD BE ATTACHED: "Unable to rule out *Plasmodium knowlesi"*

ANSWER. 22. A. These images represent *Plasmodium ovale* developing trophozoites. In the left image, note the non-ameboid ring and the fimbriated edges of the RBC. Also note the Schüffner's dots that appear early in the cycle in *P. ovale* (appear later in the cycle in *P. vivax*). In the middle image also note the non-ameboid developing ring, Schüffner's dots, and the fimbriated edges of the RBC. In the right image the stage is an early schizont with developing merozoites; also note the oval RBC shape and fimbriated edges of the RBC. The report should be: "*Plasmodium ovale* rings and schizonts; no gametocytes seen"

ANSWER. 23. C. These structures are *Plasmodium falciparum.* Note the double rings/RBC, especially in the first and third frames from the left. In the second frame from the left, note the ring that appears to be protruding from the RBC; this is more typically seen in *P. falciparum* infections. Also, in the frame on the right one can see dots in the RBC that represent Maurer's dots (not often seen). Also, in the third frame you can see the typical headphone appearance of the ring forms (double chromatin dots per ring). The report should be: *Plasmodium falciparum* ring forms; no gametocytes seen"

ANSWER. 24. C. These images are *Plasmodium malariae* images. In the left and middle frames are band form trophozoites. In the right frame is a mature

schizont containing 8 merozoites. Note that the infected RBCs are normal to small size, while RBCs of *P. vivax* and *P. ovale* are enlarged. The mature schizont (right image) is called the "daisy" configuration with the merozoites arranged in a circle around the remaining malarial pigment.

ANSWER. 25. C. These images represent *Plasmodium falciparum* ring forms. Note the multiple rings per RBC; also note in the left and right frames the accolé or appliqué forms with the ring form aligned along the side of the RBC (arrows). This is typical for *P. falciparum*. The report should be: "*Plasmodium falciparum* ring forms; no gametocytes seen"

REFERENCES

1. Garcia, L.S. 2016. *Diagnostic Medical Parasitology*, 6th Ed., ASM Press, Washington, D.C.