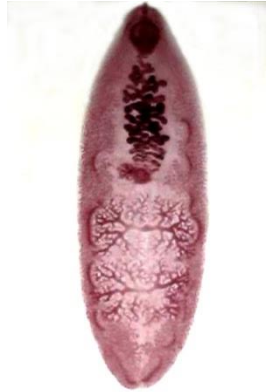
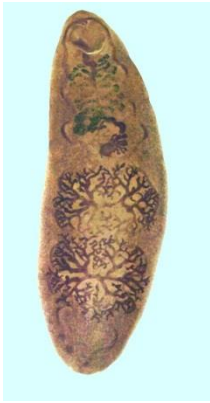
## ***Fasciolopsis buski* (Pathogen – Intestinal Trematode)**

### **Organism:**

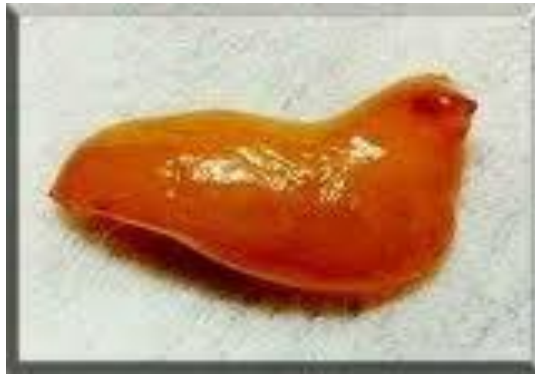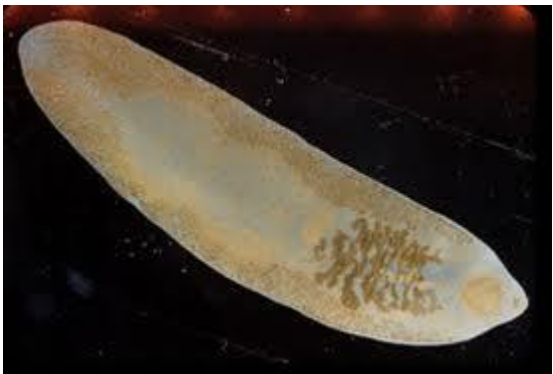Fasciolopsiasis was first noted by Busk in 1843, when worms were detected in the duodenum of a deceased East Indian sailor. *F. buski* has also been known as the giant intestinal fluke and is one of the largest parasites to infect humans, measuring 20 to 75 mm in length, 8 to 20 mm in width, and 0.5 to 3 mm in thickness.



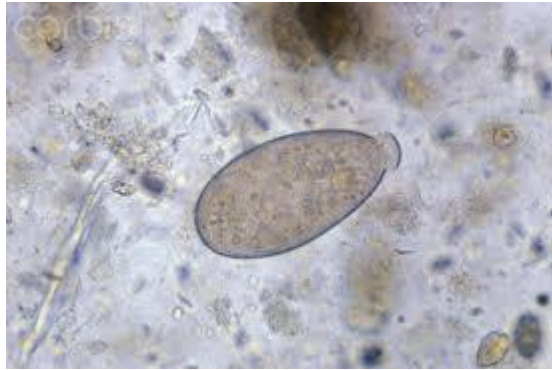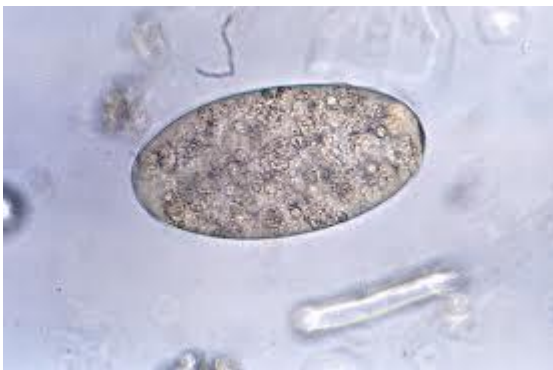Adult worms

Water Chestnut Plant

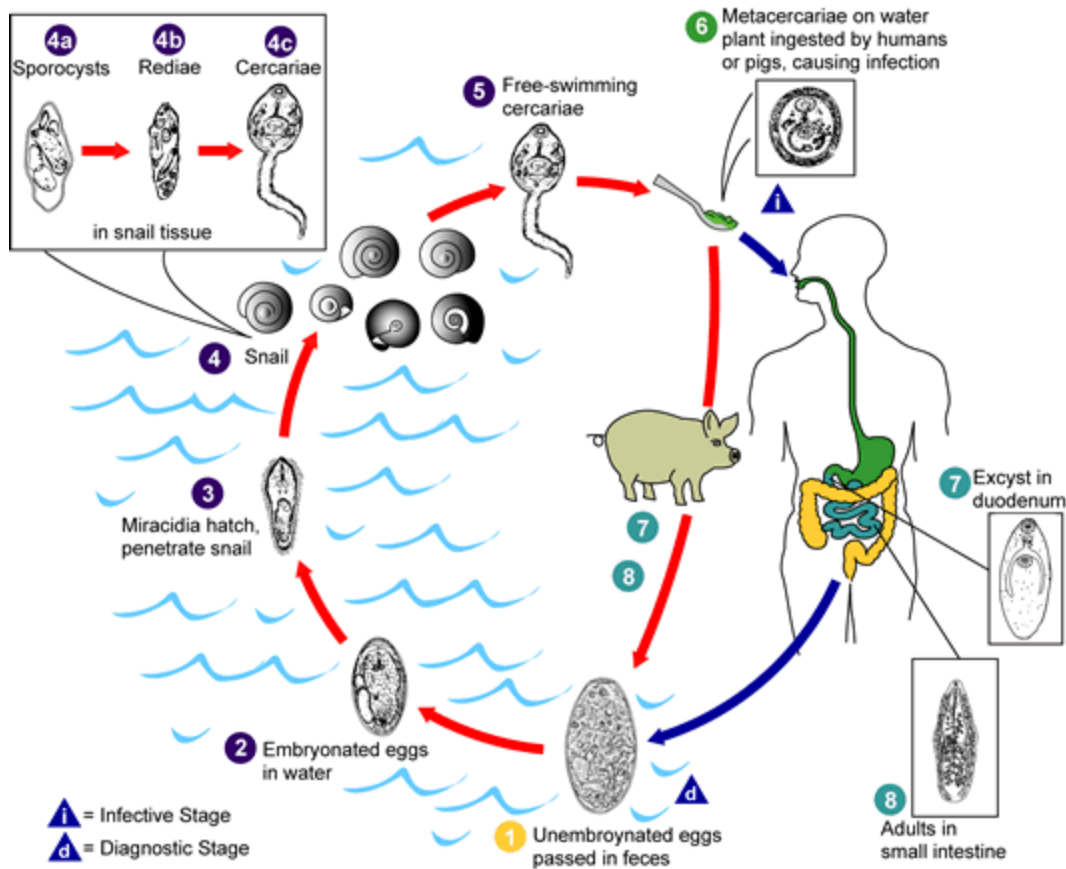
Water Chestnut



Adult worms - fresh



*Fasciolopsis buski* eggs: Note open operculum (right)



### Life Cycle:

The adult worms live in the small intestine of pigs and humans, where the worms lay unembryonated eggs that are then passed from the intestinal lumen with the feces. The eggs are ellipsoidal, operculate, and yellow-brown. They measure 130 to 140  $\mu\text{m}$  by 80 to 85  $\mu\text{m}$ , with the operculum found at the more pointed end of the transparent eggshell. Depending on the temperature, the eggs will embryonate within 3 to 7 weeks. Once in the water, the mature miracidium hatches from the egg and tries to locate the appropriate snail species to infect (*Segmentina* and *Hippeutis* spp.). Once the miracidium has penetrated the soft tissues of the snail (first intermediate host), it begins to develop into a first-generation sporocyst. The sporocyst is an elongated sac, without distinct internal structures, in which germ balls proliferate. These germ balls develop into rediae that contain a mouth, pharynx, blind cecum, and birth pore. Within the rediae, the germ balls again proliferate, developing into cercariae. Unlike some of the other intestinal trematodes, *Fasciolopsis* rediae develop a second generation of rediae before forming cercariae. Upon reaching maturity, the cercariae escape from the snail host into the water. The cercariae encyst on water plants such as water caltrops, water chestnuts, and water bamboo, where they develop into metacercariae in approximately 4 weeks. Humans become infected by ingesting the raw or undercooked plants containing the metacercariae. The metacercariae excyst, attach to the duodenal or jejunal mucosa, and develop into adult worms within 3 months. The adult life span seldom exceeds 6 months to a year.

### Acquired:

Humans become infected by ingesting the raw or undercooked plants (water chestnuts) containing the metacercariae. The metacercariae excyst, attach to the duodenal or jejunal mucosa, and develop into adult worms within 3 months.

### Epidemiology:

*F. buski* reservoir hosts include dogs, pigs, and rabbits. The infection is commonly found in Bangladesh, Cambodia, central and southern China, India, Indonesia, Laos, Malaysia, Pakistan, Taiwan, Thailand, and Vietnam; the infection has also been reported from Japan. Drainage of farm waste, use of manure for cultivation, and defecation in or near ponds or lakes that contain snails from the family *Planorbidae* (*Gyraulus*, *Polypylis*, *Segmentina*, or *Hippeutis* spp.), with water plants acting as vectors, allows the life cycle of the worm to continue. Metacercariae encyst on freshwater vegetation, such as water chestnuts, bamboo shoots, or water caltrops, and

the infection is acquired when these infested plants are consumed raw or the outer coat is peeled off the nut with the teeth, resulting in accidental ingestion.

### **Clinical Features:**

In light infections, the adults inhabit the duodenum and jejunum; in heavy infections, they may be found in the stomach and most of the intestinal tract. The attachment of worms to the mucosal wall produces local inflammation with hypersecretion of mucus, hemorrhage, ulceration, and possible abscess formation. In heavy infections, the worms may cause bowel obstruction, acute ileus, and absorption of toxic or allergic worm metabolites, producing general edema and ascites. Edema of the face may occur as a result of hypoalbuminemia secondary to malabsorption or protein-losing enteropathy. Occasionally, vitamin B<sub>12</sub> absorption is impaired, with resulting low vitamin B<sub>12</sub> levels. A marked eosinophilia and leukocytosis are commonly seen. Few symptoms are associated with light infections, but in heavier infections, the patient may experience abdominal pain and diarrhea. In heavy infections, the stools are profuse and yellow-green and contain increased amounts of undigested food, suggesting a malabsorption process. The symptoms may be confused with those of giardiasis or peptic ulcer or with other causes of bowel obstruction. Depending on the worm burden, the infection can be associated with severe cachexia and prostration and can lead to death.

### **Clinical Specimen:**

Stool: Confirmation of the infection depends on finding the large, operculated eggs in a routine stool examination

### **Laboratory Diagnosis:**

Stool: The routine sedimentation concentration is recommended. The eggs are too heavy to be recovered using the zinc sulfate flotation method.

**NOTE:** The eggs of *E. ilocanum*, *F. hepatica*, *F. buski*, and *G. hominis* are similar in size and shape; therefore, an exact identification cannot be made from examining the eggs. It is possible to detect adult worms in the stool in heavy infections when they lose their ability to remain attached to the intestinal mucosa. This egg has no opercular shoulders; therefore, it is difficult to see where the operculum "breaks" in the shell actually occur.

### **Organism Description:**

Adult: The adult worms are fleshy, dark red and elongate-ovoid and have no cephalic cone structures like that seen in the liver fluke, *Fasciola hepatica*. They measure 20 to 75 mm in length, 8 to 20 mm in width, and 0.5 to 3 mm in thickness.

### **Laboratory Report:**

*Fasciolopsis* type eggs recovered

### **Treatment:**

Although different drugs have been used for therapy, the drug of choice is praziquantel, an isoquinoline derivative that is administered orally. The drug is well tolerated; however, there may be some side effects, including abdominal pain, headache, dizziness, nausea, drowsiness, pruritus, and myalgia. These side effects usually disappear within 48 h but may be more pronounced in heavily infected individuals. The drug is administered as a single 15-mg/kg dose after the evening meal or before going to bed. A second regimen consists of 75 mg/kg/day in three doses for 1 day. Apparently, children tend to tolerate the drug better than adults. Contraindications for use include ocular cysticercosis, cerebral paragonimiasis, pregnancy, and physically demanding tasks where dizziness or drowsiness might put the patient at risk.

An alternative drug is niclosamide (Niclocide), a salicylamide derivative; alcohol should be avoided during treatment. The drug may be given for 1 or 2 days at 40 mg/kg/day (up to a maximum of 4 g). This drug is minimally absorbed from the gastrointestinal tract, and side effects include nausea, vomiting, diarrhea, and abdominal pain.

Garcia, L.S. 2007. Diagnostic Medical Parasitology, 5<sup>th</sup> ed., ASM Press, Washington, D.C.

### **Control:**

To prevent the infection, plants should be cooked or immersed in boiling water for a few seconds before they are eaten or peeled. In areas of endemicity, the use of unsterilized night soil for fertilizer should be prohibited. If these safeguards were used, the risk of infection would be considerably decreased. Control programs are not fully successful because of long-standing traditions of eating raw aquatic plants and using untreated water. Control measures are also impacted by social and economic factors, an expanding free-food market, a lack of sufficient food inspection and sanitation, and declining economic conditions.