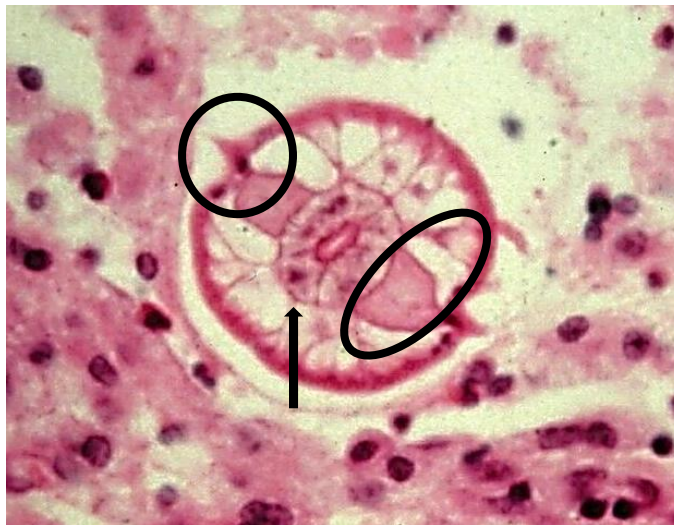
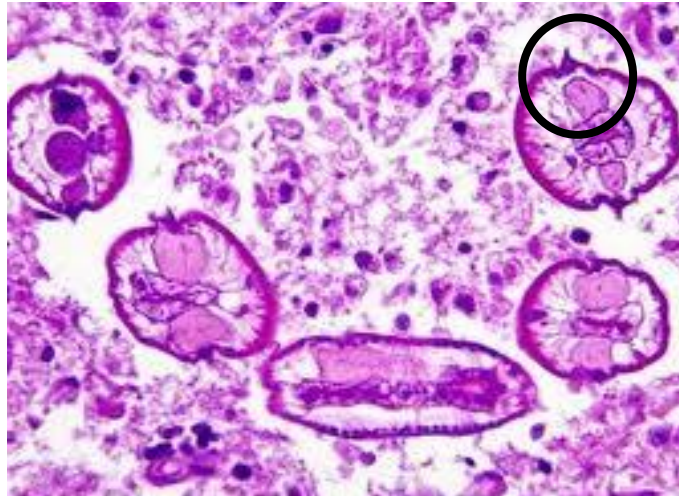

PARASITOLOGY CASE HISTORY 3 (HISTOLOGY)

(Lynne S. Garcia)

A 9-year-old immunocompetent female presented with symptoms that were consistent with appendicitis. Routine biopsy specimens from the appendectomy were examined. The following images were seen (Routine H&E).



- What possibilities should be considered?
- Do these structures explain the patient's symptoms and history? Why or why not? What additional laboratory procedures or stains could be performed?

•

Scroll Down for Answer and Discussion

Answer and Discussion of Histology Quiz #3

The top image represents cross sections of adult *Enterobius vermicularis* female worm in the appendix. Note the characteristic lateral alae (circle) that are visible

The lower image represents the intestinal lumen containing a cross section of an *Enterobius vermicularis* worm. This nematode has the meromyarian type of musculature. Note the lateral alae (circle), the excretory columns (oval) and intestine (arrow). (Armed Forces Institute of Pathology photograph.)

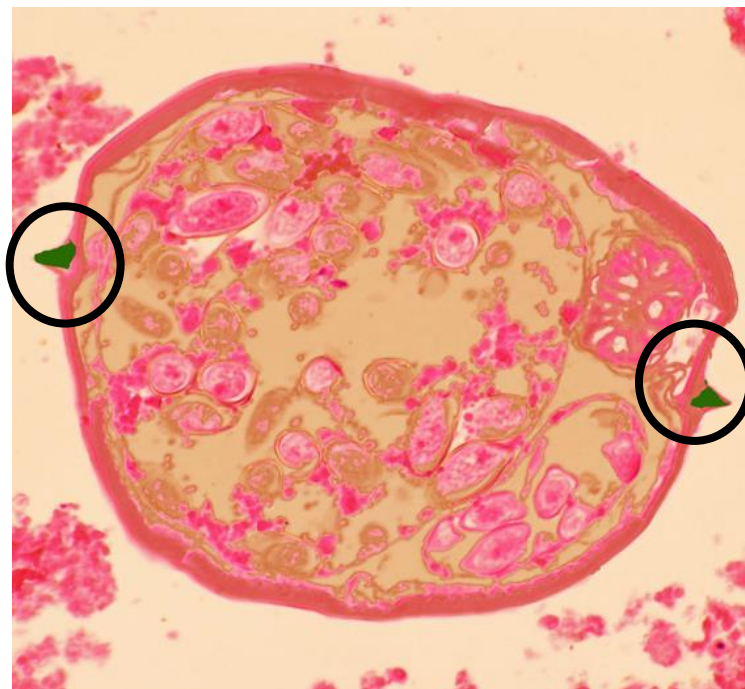These images are consistent with the pinworm, *Enterobius vermicularis* (1-5) The inflammation rate observed in appendix specimens infected by *E. vermicularis* in the literature varies from 13% to 37% (2, 3); there may be no histological evidence of acute inflammation. For the patients whose specimens were found to contain *E. vermicularis*, appendectomy is not the adequate treatment alone. Because surgery does not intend to eliminate the cause, patients must be prescribed anthelmintic medications (oral metronidazole/pyrantel pamoate) after surgery.

E. vermicularis is the most prevalent helminthic infectious agent of the gastrointestinal tract throughout the world. The relationship between *E. vermicularis* and appendicitis was first described by Dr. G.F. Still in the late nineteenth century. Generally being asymptomatic, its most common presentation is pruritus ani. On the other hand it may present with more serious sequelae like ileocolitis, enterocutaneous fistulas, urinary infections, mesenteric abscesses, salpingitis and appendicitis. *E. vermicularis* is generally found in the terminal ileum, proximal ascending colon, caecum and/or appendix. This condition is more frequently found in females with a peak in 12-year-old girls. In children with abdominal pain in the right iliac

fossa without analytical-radiological changes in the ileocaecal appendix, infection with *E. vermicularis* must be considered; medical treatment and be appropriate, thus avoiding unnecessary appendectomies.

Although the patient history of anal itching, irritability, and insomnia may suggest a pinworm infection, diagnosis depends on demonstrating the eggs or adult worms. This is normally accomplished by sampling the perianal and perineal skin with cellulose tape (Scotch tape), which is applied sticky side down to the skin. The tape is transferred to a glass slide and examined under the microscope for the presence of eggs or adult worms. Commercial paddles are also available for the collection of eggs and/or adult pinworms. Eggs are rarely found in the stool (approximately 5% of the time), and sampling of the perianal folds yields more accurate results. Since the female worms migrate on a sporadic basis, a series of four to six consecutive tapes may be necessary to demonstrate the infection. The tapes are used late in the evening, when the patient has been sleeping for several hours, or first thing in the morning before the patient takes a shower or goes to the bathroom. These samples can be taken from children at home and transported to the laboratory for examination. Because this diagnostic method is somewhat laborious, many pediatricians will treat on the basis of symptoms alone.

Comments on other stains: Lateral alae contain acid mucopolysaccharides that stain bright green (Circles) with the Movat stain, which can be especially helpful in identifying alae in degenerated worms.



References:

1. **Garcia, LS**, 2016. *Diagnostic Medical Parasitology*, 6th Ed., ASM Press, Washington, DC.
2. **Wiebe BM**. 1991. Appendicitis and *Enterobius vermicularis*. *Scand J Gastroenterol*, 26: 336-8.
3. **Budd JS, Armstrong C**. 1987. Role of *Enterobius vermicularis* in the aetiology of appendicitis. *Br J Surg* 74: 748-9.
4. **Sah SP, Bhadani PP**. 2006. *Enterobius vermicularis* causing symptoms of appendicitis in Nepal. *Trop Doct*, 36: 160-2.
5. **Chamisa I**. 2009. A clinicopathological review of 324 appendices removed for acute appendicitis in Durban, South Africa: a retrospective analysis. *Ann R Coll Surg Engl*, 91: 688-92.
6. **Expandar, L, TJ Cummings, CS Boehlke**. 2014. Unilateral microsporidia keratitis in a healthy non-contact lens wearer. *JAMA Ophthalmol* 132:822.
7. **Garg, P** 2013. Microsporidia infection of the cornea - a unique and challenging disease. *Cornea* 32 Suppl 1:S33-S38.